

# Necrotizing Fasciitis and Death Following an Insect Bite.

Dinesh M.G. Fernando<sup>1</sup>, C.I Kaluarachchi<sup>1</sup>, C.N Ratnatunga<sup>2</sup>.

<sup>1</sup>Department of Forensic Medicine, <sup>2</sup>Department of Microbiology, Faculty of Medicine, University of Peradeniya.

## Abstract

A healthy male who presented to hospital with painful swelling of the left arm following a history of insect (tick) bite, developed shock and died within 48hours. The post mortem examination revealed swelling and desquamation of skin and erythema on left arm extending below the elbow. The subcutaneous tissue was necrotic with healthy underlying muscles. Group A beta hemolytic streptococcus was isolated from post mortem swabs of the infected tissue. Histo-pathological changes were consistent with necrotizing fasciitis.

Secondary bacterial infection is an important possible complication following insect bite and a high degree of suspicion with aggressive early treatment is required in cases of necrotizing fasciitis to prevent fatalities. Both clinicians and pathologists need to be aware of this rare, rapidly fatal condition that may follow an insect bite.

Key words: Insect bite, Streptococcus, Necrotizing fasciitis, Death

## Introduction.

Insects causing stings and bites in humans include, scorpions, spiders, ticks, mites, bees, wasps, yellow jackets, hornets, and ants<sup>1</sup>. Direct envenomation and anaphylaxis are common causes for immediate reaction to an insect bite. Ticks, ants and Triatoma bugs have been reported to cause allergic reactions while bees and spiders are known to cause direct envenomation<sup>2,3</sup>. Other complications of insect stings include serum sickness reactions, neuritis, myasthenia gravis, cerebral infarction, Guillain-Barré syndrome, encephalitis, Henoch-Schönlein purpura, Reye-like syndrome, myocardial infarction, and cardiac arrhythmia<sup>2</sup>. Ticks and mites are vectors of many different pathogens including bacteria, rickettsiae, protozoa and viruses<sup>4</sup>. They may also act as reservoirs in certain infections such as rickettsioses. Case reports of tick borne bacterial infections such as rickettsioses, borreliosis, tularaemia and lyme disease are commonly reported worldwide<sup>5,6</sup>.

In addition to the various diseases transmitted by insects, another important aspect of insect bite is the injury caused by the bite. This could give rise to serious complications following secondary bacterial infection. One such rare condition is necrotizing fasciitis, which is a rapidly progressive, destructive infection of the subcutaneous tissue with a high mortality<sup>7</sup>. It is a surgical emergency which requires aggressive treatment with surgical debridement. Two cases of necrotizing fasciitis due to insect bites (not specified) have been reported from Dallas, Texas<sup>8</sup>.

We report a case where a patient developed rapidly fatal necrotizing fasciitis following a probable 'tick bite'.

## Case report.

A 48 year old, previously healthy male developed itching of the left axilla and noticed a 'tick', which he removed. The next day he developed fever and subsequently noticed swelling and severe pain of the left upper arm which spread to the forearm by evening. He was admitted to the local hospital and was transferred to a tertiary care hospital the same day. On admission to the hospital the patient was complaining of severe pain and had swelling and bluish discoloration of the entire left upper limb.

Investigations revealed a White Cell count of  $7.2 \times 10^6$  with 66% Neutrophils. Random blood sugar was 6.7mmol/L. The patient was started on prednisolone and intra venous Co-Amoxiclav. On day two following the bite the patient developed difficulty of speech in the morning, followed by shortness of breath and cold peripheries and had a cardio-respiratory arrest at 1.15 pm. All resuscitation attempts failed and death was confirmed at 1.45pm.

Post-mortem examination revealed swelling and desquamation of skin and erythema on left arm extending to below the elbow. (Fig: 1 & 2)

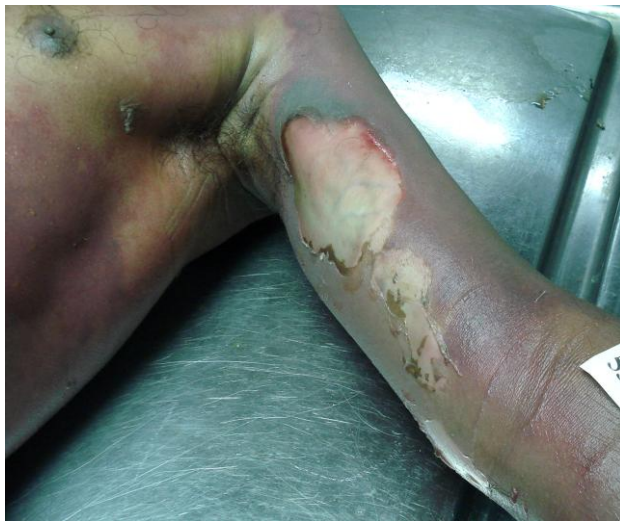

Fig:1 Swelling and desquamation of skin on left arm

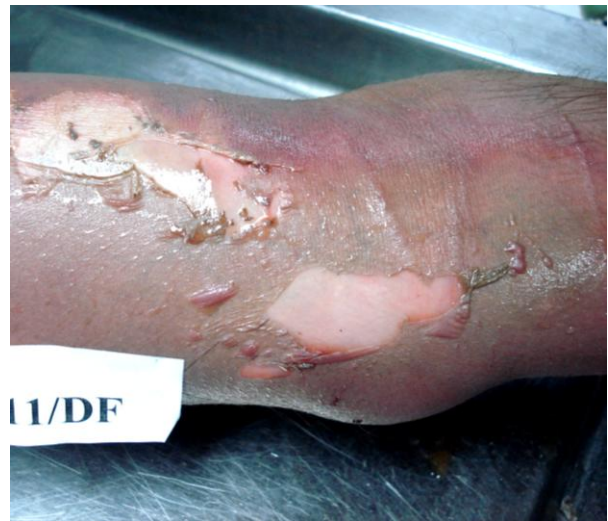

Fig:2 Desquamation of skin and erythema on left elbow

Mid arm circumference was 25 cm on the right side and 30 cm on the left side. There were two areas of loss of superficial skin on the left axilla which were small ( $1 \times 0.5$ cm and  $0.2 \times 0.2$ cm), circular and consistent with that of an insect bite. (Fig: 3) The subcutaneous tissue was necrotic while on deep dissection the underlying muscle appeared normal. (Fig: 4)

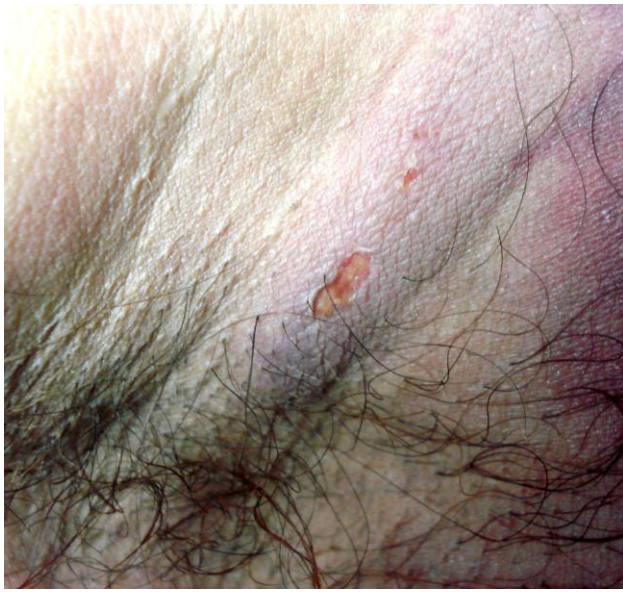

Fig: 3 Site of insect bite in the left axilla

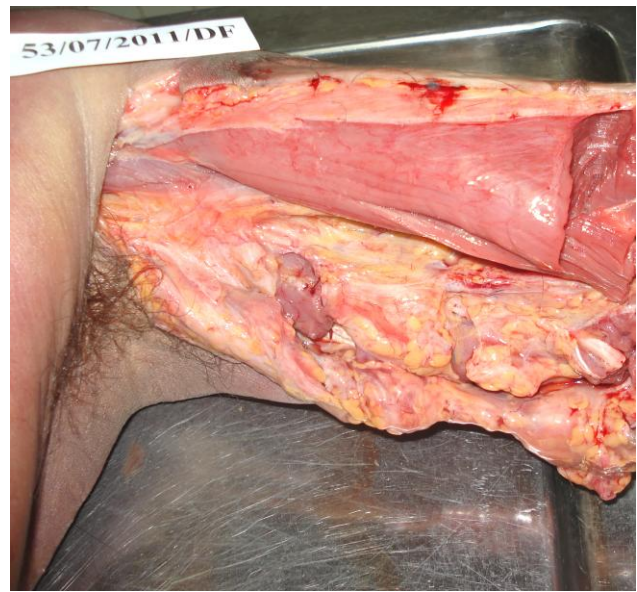


Fig: 4 Necrotic subcutaneous tissue with healthy underlying muscle

Examination of the respiratory system showed a congested trachea and larynx with oedema of the vocal cords. Lungs were congested and oedematous. Heart and coronary arteries were unremarkable. Brain showed glistening cerebral oedema and congested blood vessels. Liver was fatty. Spleen was not enlarged or soft. Kidneys were swollen, pale and had an indistinct cortico-medullary junction.

### Investigations

An incision with a sterile blade was made on the left arm at the site of bluish discolouration and a swab taken from the necrotic material for microbiological examination. Direct smear showed gram positive cocci and pus cells. Culture on blood agar gave a pure growth of group A beta haemolytic streptococcus. On histological examination, sections taken from the ulcerated area showed necrosis of the epidermis causing separation of the dermo-epidermal junction, and the junction zone showed the presence of fibrin and extensive neutrophil infiltration which extended from the dermis to the sub cutaneous tissue. The underlying muscle was normal. A few foci of acute fat necrosis and necrosis of collagen were noted. Thrombi were seen in the veins of the sub cutaneous tissue and an artery also showed the presence of an early thrombus. Features seen were consistent with necrotising fasciitis. Vitreous humour  $\text{Na}^+$  concentration was 116 mmol/L and  $\text{K}^+$  was 11 mmol/L. Dengue anti bodies were negative in blood. Toxicological examination for common poisons was negative.

Death was attributed to necrotizing fasciitis due to *Streptococcus pyogenes* following an arthropod bite.

### Discussion

Twenty seven species of hard ticks belonging to nine genera have been reported from Sri Lanka. Of these, genus *Haemaphysalis* is the most common. *Dermacemor auratus* and *Hyalomma marginatum isaaci* have been reported in the ear canal of patients in Kandy district, Sri Lanka<sup>9</sup>.

Necrotizing fasciitis can be classified according to the anatomical location, depth of infection and microbial cause. Type 1 is polymicrobial while type 2 is monomicrobial. Several organisms

are implicated in the pathogenesis of type 2 necrotizing fasciitis, of which streptococcal species alone or in combination with *Staphylococcus aureus* is the most common. Type 3 infection is caused by *Vibrio vulnificus*<sup>10</sup>. Enterococci and enterobacteriaceae have also been associated with necrotizing fasciitis<sup>11</sup>. The type of the organism may also vary with the site involved, *S. pyogens* being the most commonly isolated organism from the lesions of the extremities<sup>12</sup>. Initial injury leading to necrotizing fasciitis is a minor trauma in the majority of patients. Minor abrasions have been identified as the most common initial injury leading to necrotizing fasciitis, with cuts and bruises also being common<sup>8</sup>. The extremities have been identified as the most common location of infection, with lower limb involvement being more common than upper limb involvement<sup>11</sup>.

The most commonly encountered problem in necrotizing fasciitis, as in this patient, is its lack of well specified clinical symptoms and rapid progression. Fever, cellulitis and pain out of proportion to the physical findings are the most commonly reported symptoms. Hypotension, tachycardia, rapid progression, blistering, necrosis, extreme local tenderness, poor therapeutic response, tissue crepitations and an altered level of consciousness must alert the clinician of necrotizing fasciitis in patients otherwise thought to have cellulitis and treatment should not be delayed<sup>13</sup>. Of the initial investigations serum creatinine kinase level indicates deeper soft tissue infection and a rising level co-relates well with the degree of necrotizing fasciitis<sup>14</sup>. Had this investigation been done in this patient it would have facilitated the diagnosis of necrotizing fasciitis.

On admission, this patient had been started on intra-venous Co-Amoxiclav. Although *S. pyogens* is generally extremely sensitive to penicillin, the clinical response can be slow or unsatisfactory in invasive streptococcal disease<sup>15</sup>, and current evidence suggest that clindamycin alone or in combination with penicillin has higher efficacy and leads to reduced mortality in these patients<sup>14</sup>. Furthermore, antibiotics may temporarily mask the underlying pathology and according to the literature a delay in surgical debridement has a significant adverse impact on survival. A Singapore research team has identified a delay of more than 24 hours from admission to surgery as the only independent predictor of mortality in patients with necrotizing fasciitis<sup>11</sup>.

## **Conclusion**

Necrotizing fasciitis is an infection with a high mortality. Early recognition of the condition with relevant investigations and adequate antibiotic therapy with early tissue debridement may have saved this patient.

## **Acknowledgement**

We would like to gratefully acknowledge the help and advice given by Prof. Neelakanthi Ratnatunga of the Department of Pathology, Faculty of Medicine, University of Peradeniya.

## References

---

- <sup>1</sup> Brinker D, Hancox JD, Bernardon SO. Assessment and Initial Treatment of Lacerations, Mammalian Bites, and Insect Stings. *AACN Clinical Issues* 2003; 14: 401-410
- <sup>2</sup> Moffitt JE. Allergic Reactions to Insect Stings and Bites. *Southern Medical Journal* 2003; 96: 1073-1079.
- <sup>3</sup> Brown AFT, Hamilton DL, Tick bite anaphylaxis in Australia. *Journal of Accident and Emergency Medicine* 1998; 15: 111-113.
- <sup>4</sup> Parola P, Raoult D. Ticks and tick borne bacterial diseases in humans: an emerging infectious threat. *Clinical Infectious Diseases* 2001; 32: 897–928.
- <sup>5</sup> Bratton RL. Tick-Borne Disease. *American Family Physician* 2005; 71: 2323-2330.
- <sup>6</sup> Gayle A, Ringdahl E. Tick-borne Diseases. *American Family Physician* 2001; 64: 461-466.
- <sup>7</sup> Kaul R, McGeer A, Low DE, et al. Population-based Surveillance for Group A Streptococcal Necrotizing Fasciitis: Clinical Features, Prognostic Indicators, and Microbiologic Analysis of Seventy-Seven Cases. *The American Journal of Medicine* 1997; 103: 18-24.
- <sup>8</sup> William J. Walter J. Wyrick. Necrotizing Fasciitis. *Annals of Surgery* 1970; 172: 957-964.
- <sup>9</sup> Edussuriya BD, Weilgama DJ. Case reports: intra-aural tick infestations in humans in Sri Lanka. *Transactions of the Royal Society of Tropical Medicine and Hygiene* 2003; 97: 412-413.
- <sup>10</sup> Sarani B, Strong M, Pascual J, Schwab CW. Necrotizing Fasciitis: Current Concepts and Review of the Literature. *Journal of the American College of Surgeons* 2009; 208: 279-288.

- 
- <sup>11</sup> Wong C, Chang HC, Pasupathy S, et al. Necrotizing Fasciitis: Clinical Presentation, Microbiology, and Determinants of Mortality. *The Journal of Bone & Joint Surgery* 2003; 85-A: 1454-1460.
- <sup>12</sup> Green RG, Dafoe DC, Raffin TA. Necrotizing Fasciitis. *Chest* 1996; 110: 219-229
- <sup>13</sup> Kihiczak GG, Schwartz RA, Kapila R. Necrotizing fasciitis: a deadly infection. *European Academy of Dermatology and Venereology* 2006; 20: 365–369.
- <sup>14</sup> Stevens DL. The Flesh-Eating Bacterium: What's Next?. *The Journal of Infectious Diseases* 1999;179: 366–74
- <sup>15</sup> Barnham M, Holm SE. Serious *Streptococcus pyogenes* disease. *Clinical Microbiology and Infection* 1997; 3: 250-260.